Xerosis • Condition caused by the skin's loss of natural moistureizing factors and loss of moisture from the strtum corneum and intercellular matrix—occurs primarily on heels and plantar surface of the feet • Common in individuals who have decreased function/loss of function of sweat glands on feet • Appears as excessively dry, rough, cracked skin • There may be scaling, flaking, chapping and pruritis • Can lead to fissures which serves as portal of entry for bacteria	
Ankle Flare/Malleolar Flare • Visible capillaries around the medial malleolus • Caused by the distention of small veins	 
Atrophe Blanche • Smooth, white plaques of thin, speckled atrophic tissue with tortuous vessels on the ankle or foot with hemosideran-pigmented borders • Sometimes mistaken for scars • Ulcers in this are are small, very painful and difficult to heal	

Callous

- Natural protective response to repetitive stress
- Characterized by thickened hyperkeratotic skin
- Can increase pressure 25-30% which can result in an ulcer below the callused area

Charcot j-oint

- Intra-articular fractures & bone fragmentation in foot
- Three stages:

Development: usually initiated by minor trauma—fracture occurs along with joint effusions an edema

Coalescence: reduced edema, absorption of fine debris and helaing of fractures

Reconstruction: repair and remodelling of bones along with fusion and rounding of large bone fragments and decreased joint mobility

- Prone to increased plantar pressure
- Possible bone/joint collapse

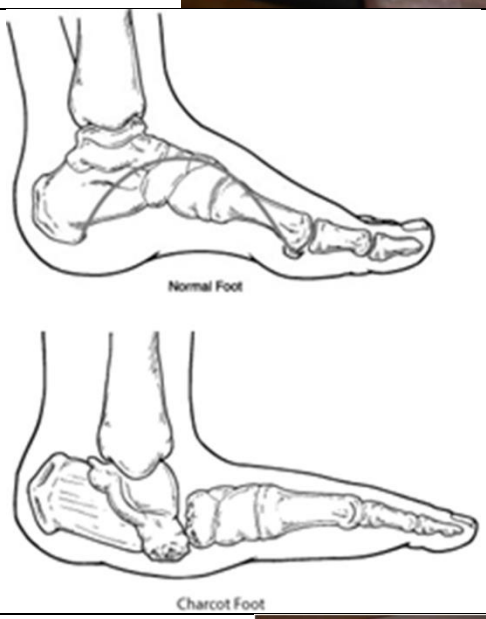

Dependent rubor

- Position-related colour change
- Leg is raised 60 degrees for 15-60 seconds while client supine
- Return leg to dependent position
- Ischemic klimb will slowly turn from white to pink and porgress to deep purple-red colour as the de-oxygenated blood accumulates in the dilated skin capillaries

Dystrophic nail bed changes

- Thickened, yellowed nails
- Brittle
- May indicate lowere extremity arterial disease, however can also be affected by age and fungal infections

Elevational pallor

- Position-related colour change to one or both legs
- With patient supine, raise leg 60 degrees for 15-60 seconds.
- Observe the colour on the soles of the feet
- Normally, colour should not change, but when perfusion is impaired the extremity will become pale in fair skinned individuals and gray/ashen in dark skinned individuals

Fixed ankle joint

- Less than 0 degrees of ankle joint dorsi-flexion
- Increases pressure on sole of foot
- High plantar pressure

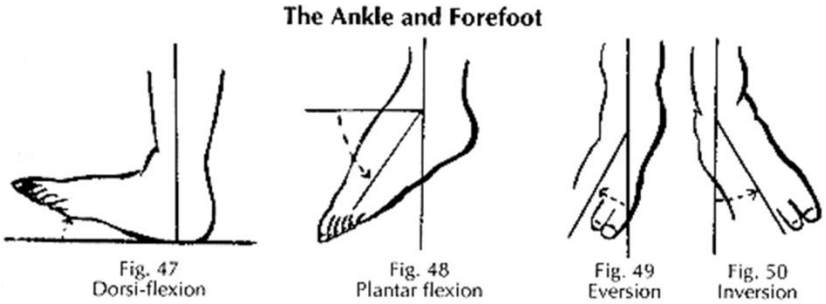

Hammer Toe

- Contracture of the proximal joint
- Often seen in second metatarsal head when bunion slants large metatarsal toward and under it

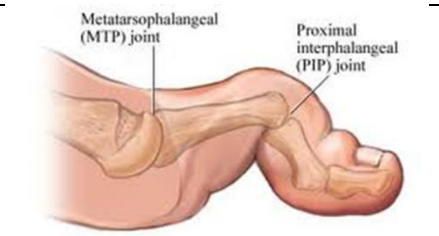

Mallet Toe • Contracture of the distal joint, closest to the end of the toe	 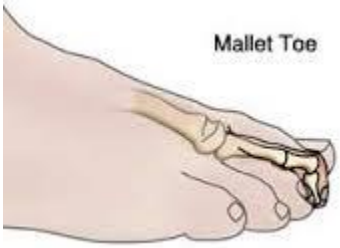
Claw Toe • Contraction of both metatarsal joints	 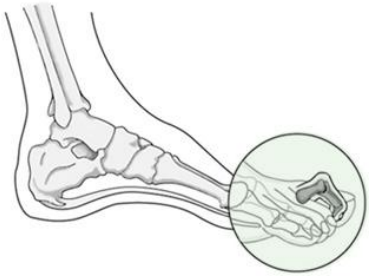
Hemosideran Staining • Discolouration of soft tissue in gaiter area • Caused by the breakdown of red blood cells that are trapped in soft tissue releasing the pigment hemosideran	
Hyperkeratosis • Build up of hard, white/grey tissue surrounding a wound • Similar to “scale” but a thicker build-up • Flakey, cracked and dry in appearance	 

Lipodermatosclerosis • Fibrosis/hardening of the soft tissue in the lower leg that abnormally narrows the affected area • Woody/hard texture usually confined to gaiter area • Indicates long-standing venous insufficiency • Caused by the combination of fibrin deposits, compromised fibrinolysis, and collagen deposits in response to growth factors producted by activated WBC's	
Pes Cavus • High arch or instep	
Pes Planus • Flat foot	
Prominent Metatarsal Heads • Fat pads beneath metatarsal heads atrophy or dilocate increasing the pressure beneath them • Occur if one of the metatarsal bones are longer or lower than its neighboring bones	

Variose Veins • Swollen, twisted veins that appear blue—usually located on back of calf or medial aspect of leg • Precede valvular incompetence		
Venous Stasis Dermatitis • Inflammation of the epidermis and dermis on lower extremity • Characterized by crusting, scaling, weeping, erythema, erosions and intense itching. • May be acute/chronic • Often confused with cellulitis • Caused by activated leukocytes trapped in the fibrin cuffs releasing inflammatory mediators • Increases risk of developing contact sensitivity because the skin is chronically inflamed.	**Wet**	
	Dry	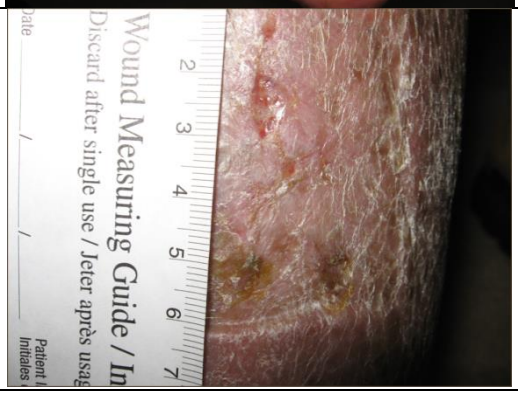

Location of Pulses